ResearchGate

See discussions, stats, and author profiles for this publication at: https://www.researchgate.net/publication/258854513

Vulvar cancer surgery

Article *in* Current opinion in obstetrics & gynecology · November 2013

DOI: 10.1097/GCO.0000000000000033 · Source: PubMed

CITATIONS
11

READS
243

2 authors:

Glauco Baiocchi
Hospital A. C. Camargo
78 PUBLICATIONS **237** CITATIONS

SEE PROFILE

Rafael Malagoli Rocha
Universidade Federal de São Paulo
181 PUBLICATIONS **1,236** CITATIONS

SEE PROFILE

Available from: Rafael Malagoli Rocha
Retrieved on: 24 August 2016

Vulvar cancer surgery

Glauco Baiocchi[a] *and Rafael M. Rocha*[b]

Purpose of review
Surgical treatment of vulvar cancer has been shifted from ultraradical procedures associated with huge morbidity to less extensive surgery with better psychosexual result and less morbidity, without compromising survival. The authors review and discuss the recent literature regarding the surgical management of vulvar squamous cell carcinoma.

Recent findings
Surgery remains the cornerstone in the treatment of vulvar cancer. Radical vulvectomy with inguinofemoral lymphadenectomy has been replaced by radical local excision with sentinel node procedure for early disease. However, the role and distance of pathological margins are still on debate. Recent results from a large prospective trial corroborate the safety of sentinel node biopsy for early disease, even after primary tumor resection. An experienced team should perform sentinel node procedure using combined technique (blue dye and lymphoscintigraphy) and ultrastaging pathology. Moreover, midline tumors still need lymph node biopsy from both groins.

Summary
Primary vulvar cancer may be safely treated with radical/wide local resection. In case of other suspicious lesion or multifocal disease, radical vulvectomy is performed. Patients with unifocal disease, tumor size less than 4 cm, and clinically negative groins are candidates to sentinel node procedure. In the case of clinically positive node or sentinel node metastasis, a systematic inguinofemoral lymphadenectomy should be performed.

Keywords
sentinel node biopsy, surgery, vulvar cancer

INTRODUCTION

Vulvar cancer accounts for approximately 3–5% of all gynecological malignancies and the majority of cases are squamous cell carcinoma [1,2].

Surgery is the cornerstone in the treatment of vulvar cancer and prognosis is mostly linked to the presence of inguinal lymph node metastasis [3,4]. The current management of vulvar cancer depends on the extension of disease, and includes primary tumor resection with safety margin as well as inguinofemoral lymph node staging [5]. If lymph node metastasis is found, the standard postoperative therapy is inguinal and pelvic radiotherapy (Fig. 1) [5].

Because of the low incidence of vulvar cancer, a small number of randomized trials is evaluable and some controversies still exist regarding the best treatment approach. In the present article, the authors review and discuss the recent literature regarding the surgical management of vulvar squamous cell carcinoma, and further propose some recommendations.

SURGICAL MANAGEMENT OF VULVAR CANCER

Surgery is the most important treatment tool in vulvar cancer, and includes both primary tumor resection and inguinofemoral lymph node staging. For patients with primary lesion less than 2 cm in size and depth of invasion of less than 1 mm (stage IA), lymph node staging may be omitted, as there is a very low risk of lymph node involvement [6–8]. In the case of larger tumors, the surgical staging of inguinofemoral lymph nodes is indicated.

Moreover, primary groin radiotherapy in clinically negative lymph nodes correlated to higher

[a]Department of Gynecologic Oncology and [b]Department of Anatomic Pathology, AC Camargo Cancer Center, Sao Paulo, Brazil

Correspondence to Glauco Baiocchi, MD, PhD, Departamento de Ginecologia Oncológica, AC Camargo Cancer Center, Rua Antonio Prudente, 211, 01509-010, São Paulo, Brazil. Tel: +55 11 2189 5110; fax: +55 11 2114 6072; e-mail: glbaiocchi@yahoo.com.br

Curr Opin Obstet Gynecol 2014, 26:9–17

DOI:10.1097/GCO.0000000000000033

Copyright © Lippincott Williams & Wilkins. Unauthorized reproduction of this article is prohibited.

KEY POINTS

- Surgery is the cornerstone for staging and treatment of vulvar cancer.
- Primary tumor may be safely treated with wide local resection and safe margins.
- Patients with unifocal disease, tumor size less than 4 cm, and clinically negative lymph node should have sentinel node procedure.
- In the case of clinically positive lymph node or positive sentinel node, a systematic inguinofemoral lymphadenectomy should be performed.

groin recurrence rate and worst survival compared with surgery [9,10].

En bloc resection

In the early 20th century, Taussig [11] and Way [12] introduced the concept of radical vulvectomy with 'en bloc' resection of bilateral inguinofemoral and pelvic lymphadenectomy. As the prognosis had improved with the 'en bloc' technique, it became the standard surgical treatment for vulvar cancer [2].

The 'en bloc' radical vulvectomy was not only mutilating, but also related to severe morbidity. Therefore, many efforts were taken to modify this surgical approach. The aim was to reduce morbidity and increase the cosmetic result, without compromising the outcome [2,5,13–15].

Triple incision technique

Primary lesion resection and inguinofemoral lymphadenectomy performed by separate incisions emerged as an alternative approach for the 'en bloc' resection, as lymph node dissemination might occur through lymphatic embolization rather than lymphatic continuity (Fig. 2) [2].

The separate incisions technique resulted in lower complication rates [15]. However, the main concern laid on its safety, more specifically the risk of 'skin bridge' recurrence [16].

In an important study, De Hullu *et al.* [17] have found significantly lower prevalence of fatal groin or 'skin bridge' relapses for 'en bloc' surgery (1.3%) compared with separate incisions (6.3%). However, there was no impact on survival. Yet, some other groups have described low groin recurrence rates after 'en bloc' inguinofemoral lymphadenectomy [3,18], and others reported 'skin bridge' recurrences even in patients with negative lymph node [16,19–24].

Despite the results from some studies that suggest a higher rate of groin relapses after triple incision technique, the overall risk of 'skin bridge' recurrence is low and no definitive data demonstrated that the outcome is compromised. Moreover, a Cochrane

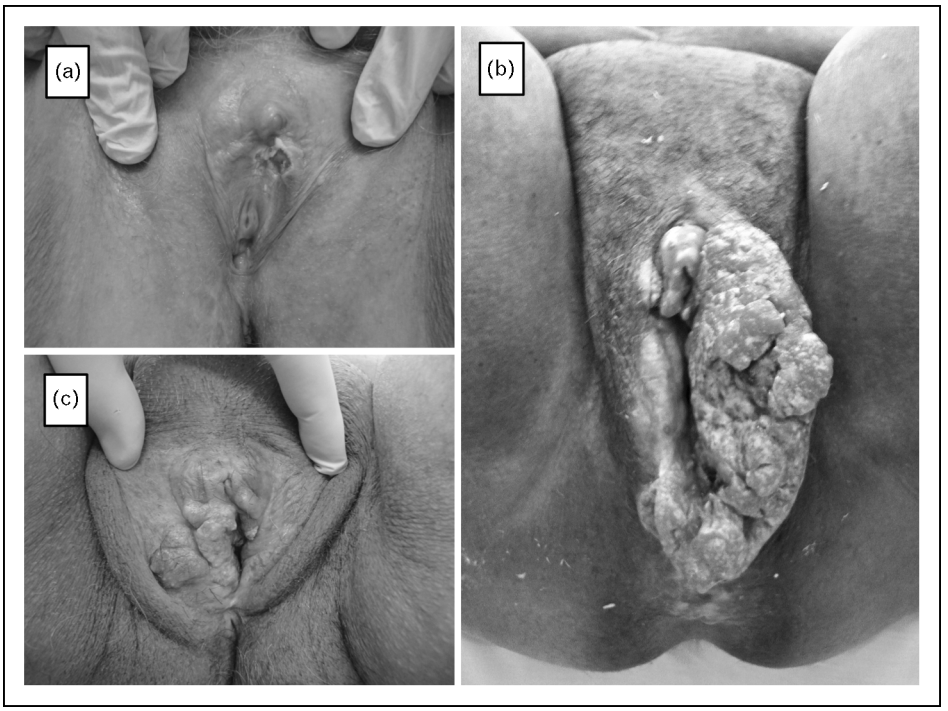

FIGURE 1. (a) Unifocal early-stage vulvar squamous cell carcinoma; (b) locally advanced vulvar cancer; and (c) multifocal early-stage vulvar cancer.

Copyright © Lippincott Williams & Wilkins. Unauthorized reproduction of this article is prohibited.

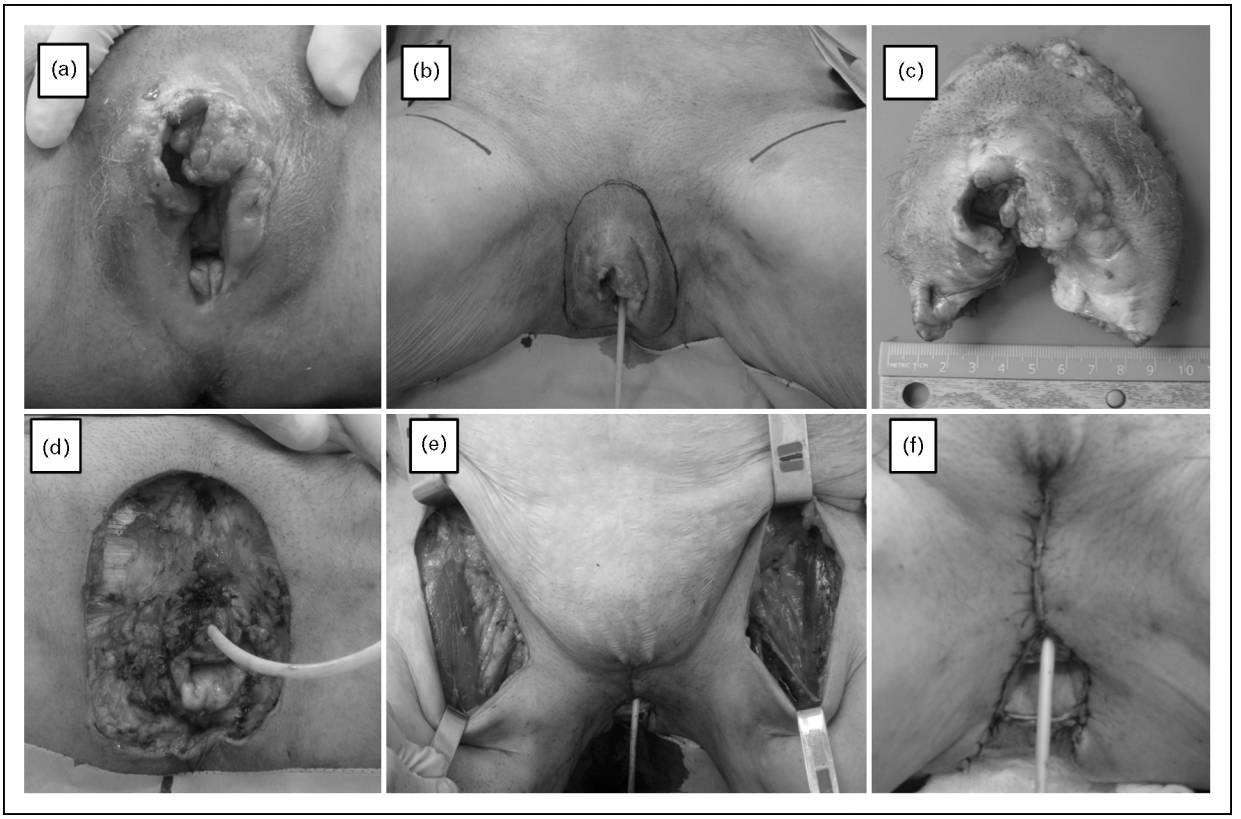

FIGURE 2. (a) Large ulcerated vulvar cancer case with extension to distal urethra; (b) ink mark on skin before triple incision technique; (c) aspect of the resected primary tumor; (d) aspect of the primary site after radical vulvectomy; (e) aspect after full inguinofemoral lymphadenectomy with separate incisions; and (f) wound closure.

review showed a 'skin bridge' recurrence rate of less than 1% for patients without lymph node metastasis, and suggested that separate incisions may be considered a safe procedure (Fig. 3) [25].

In our opinion, considering the higher complication rates of the 'en bloc' technique and the lack of power of the studies that support the higher recurrence rates for triple incision surgery, the use of separate incisions remains as our preferable surgical technique.

Wide local excision and surgical margins

After the introduction of separate incisions technique, removal of all external genitalia was still performed until the description of radical/wide local excision. No randomized trial has been performed comparing radical vulvectomy to wide local excision; however, oncologic safety seems to be comparable for early-stage disease (Fig. 4) [25–27].

However, the extent of the tumor-free resection margins after wide local excision is still under debate. Heaps *et al.* [28] suggested that pathological margins of less than 8 mm had 50% local recurrence rate. Moreover, De Hullu *et al.* [17] showed no local recurrence when pathological margins were greater than 8 mm, whereas 22.5% when free margin was at least 8 mm ($P = 0.002$). They recommended a double surgical margin (2 cm). Further, Chan *et al.* [29] also had no local recurrence after at least 8 mm margin distance and 23% when margin was less than 8 mm.

As pathologic margin seemed to be important, Palaia *et al.* [30] prospectively addressed the correlation between macroscopic and microscopic margin. Microscopic margin of 8 mm was achieved in 83% of cases when macroscopic measurement was 1 cm, in 91% when it was 1.5 cm, and in 98% when it was 2 cm. These findings corroborate De Hullu *et al.*'s [17] suggestion of safe macroscopic margin of 2 cm.

Recently, Ioffe *et al.* [31▪] correlated the margin status of the original excisional tumor and histology of the re-excision specimen for close or positive margins. After re-excision, one of 24 (4%) patients with negative margins (>1 mm and <10 mm), two of 27 (7%) patients with vulvar intraepithelial neoplasia-positive margins, and 11 of 33 (33%) patients with carcinoma-positive margins were found to still have carcinoma in the re-excision histology. They had 10% of local recurrence; however, 88% occurred

Copyright © Lippincott Williams & Wilkins. Unauthorized reproduction of this article is prohibited.

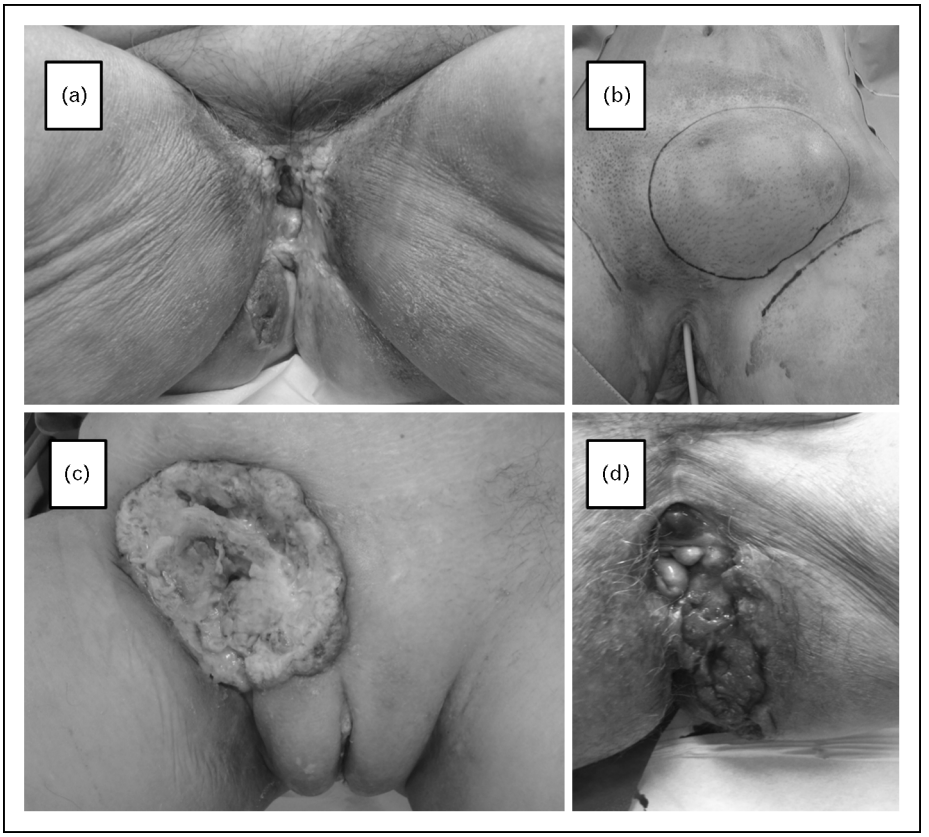

FIGURE 3. (a) Local recurrence found 9 years after radical 'en bloc' resection; (b) inguinal recurrence after radical vulvectomy and groin lymphadenectomy with separate incisions; (c) aspect of local and inguinal recurrence not suitable to surgical treatment; and (d) local relapse 5 years after radical vulvectomy by separate incisions.

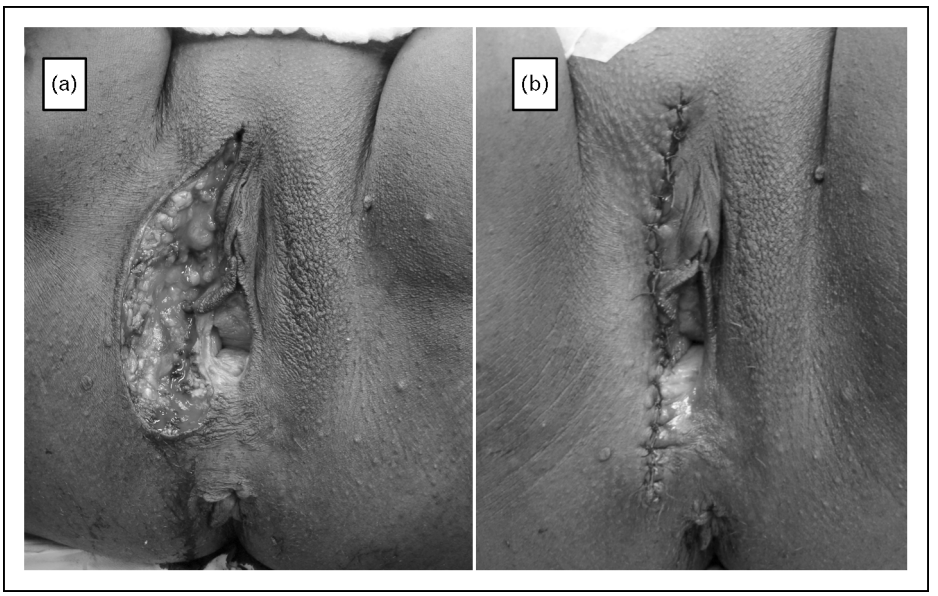

FIGURE 4. (a) Aspect of radical local resection with hemivulvectomy for early-stage disease and (b) satisfactory cosmetic appearance of the remaining external genitalia.

Copyright © Lippincott Williams & Wilkins. Unauthorized reproduction of this article is prohibited.

in the contralateral vulvar side and may probably be because of a secondary lesion.

Nevertheless, other studies failed to show any impact on margin distance and prognosis [32]. Woelber *et al.* [33] published an intriguing study of 102 patients, in which margin distance had no significant impact on the progression-free survival when analyzed as either a continuous variable or divided in three groups (<3 mm, ≥3 mm to <8 mm, and ≥8 mm). Moreover, vulvar recurrence rate did not differ between resection with margin of less than 8 mm (11.1%) compared to at least 8 mm (10%).

These findings contrast to the current recommendations. The authors argue that after complete resection of the tumor, free margins may have just minor value. However, in Ioffe *et al.*'s [31▪] study, they still had one of 24 (4%) patients with tumor left after negative margins excision. Moreover, it is important to recognize that many recurrences might be second primary tumors rather than a recurrence, as most of the local recurrences occur after 2 years of follow-up [34,35] and at a site different from the primary tumor [31▪,36].

Finally, Viswanathan *et al.* [37▪▪] recently published a large series ($n = 205$) that analyzed the risk of recurrence regarding not only margin status, but also adjuvant radiotherapy. They noted 4-year vulvar free-recurrence rate for patients with negative ($n = 69$; ≥1 cm), close ($n = 116$; <1 cm), and positive margins ($n = 20$) of 82, 63, and 37%, respectively ($P = 0.005$). About 20% of patients with close or positive margins received vulvar radiotherapy. Further, those who received a dose of at least 56 Gy had a lower risk of local relapse than those who received 50.4 Gy or less ($P = 0.05$). They concluded that recurrences were noted with margins up to 9 mm.

Despite the current controversy, we recommend radical/wide local resection for primary tumor treatment. In the case of other suspicious lesion or multifocal disease, radical vulvectomy should be performed. Regarding tumor-free resection margins, we still suggest intended surgical margins of 2 cm and final pathological margin of at least 1 cm. However, in some special situations such as tumors near the urethra or anus, final pathological margins of less than 1 cm may be considered.

GROIN SURGERY

Inguinal lymph node metastases are expected in 25–30% of vulvar cancer patients, and consequently, the majority of patients will be overtreated by radical groin lymphadenectomy [2,4,5]. Furthermore, after systematic inguinofemoral lymphadenectomy, recurrence in the groin as the initial site is an unusual event (Fig. 3) [2].

In an attempt to decrease the morbidity of groin dissection, some studies evaluated the outcome after only superficial inguinal lymphadenectomy, as theoretically the superficial nodes should be the first to be involved. However, the expected recurrence rate after superficial lymphadenectomy was up to 8.6%, with an overall relapse rate of 5.3% [38–41]. Thus, a full inguinofemoral lymphadenectomy is still recommended rather than only superficial lymphadenectomy for clinically negative patients in whom sentinel node biopsy is not indicated.

Sentinel node procedure

Sentinel node dissection has emerged as the preferred approach for patients with clinically negative nodes. In a systematic review, Selman *et al.* [42] noted detection rates with Tc-99m that ranged up to 100%, with pooled sensitivity and specificity of 97 and 100%, respectively. A high detection rate is expected (up to 100%), especially after using the combined technique (Fig. 5).

In some cases, the false-negative rate of sentinel node biopsy may be explained by the presence of positive groin metastases that primarily obliterate the lymph flow and cause bypassing of the sentinel node [43]. Preoperative imaging can help to detect gross nodal involvement. Patients with enlarged or suspicious groin lymph node should have either core-biopsy or fine-needle aspiration cytology in order to exclude metastatic lymph node. All enlarged nodes should also be resected during the surgical procedure, even if it is not the sentinel node (Fig. 6) [44].

In 2008, Van der Zee *et al.* [45] published a large, prospective, multicenter trial [Groningen International Study on Sentinel Nodes in Vulvar Cancer (GROINSS-V)] that included 403 patients with tumor size less than 4 cm, stromal invasion greater than 1 mm, and clinically negative lymph nodes. All patients received sentinel node procedure with combined technique (radioactive tracer and blue dye) and for those with negative sentinel node, systematic lymphadenectomy was omitted. After a median follow-up of 35 months, groin recurrence rate was only 2.3% for unifocal disease. Yet, half of the eight local failures could be further explained. The groin recurrence rate was at least comparable to that reported for patients with early-stage vulvar cancer treated with groin lymphadenectomy [46,47]. The sentinel nodes were analyzed by ultrastaging technique (three sections per mm and cytokeratine AE1/AE3 immunostaining) and 41.7% of metastases were diagnosed by this method. As expected, the

Copyright © Lippincott Williams & Wilkins. Unauthorized reproduction of this article is prohibited.

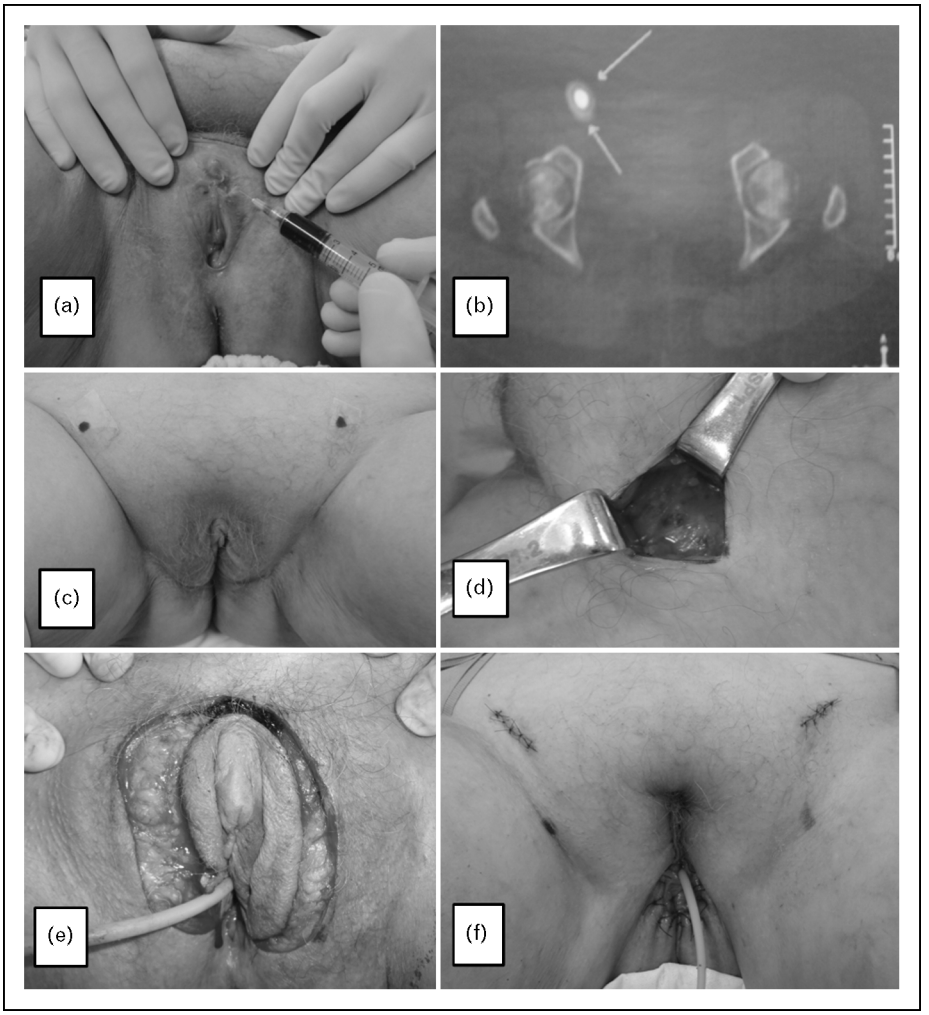

FIGURE 5. (a) Injection of blue dye around the midline primary tumor of less than 4 cm; (b) lymphoscintigraphy showing the sentinel node of the right groin; (c) skin ink mark of the bilateral sentinel lymph node sites; (d) aspect of the sentinel node colored with the blue dye in the left groin; (e) aspect of the vulva during primary tumor resection; and (f) aspect after primary tumor resection and bilateral sentinel lymph node biopsy.

FIGURE 6. (a) Example of suspicious enlarged inguinal lymph node found in pelvic computed tomography. (b) Local aspect after systematic right inguinofemoral lymphadenectomy with saphenous vein preservation.

Copyright © Lippincott Williams & Wilkins. Unauthorized reproduction of this article is prohibited.

complication rates were significantly lower for patients who did not need inguinofemoral lymphadenectomy.

In the GROINSS-V study, nonsentinel node involvement occurred in 21% of the patients with a metastatic sentinel node. Oonk *et al.* [48] demonstrated from the GROINSS-V data that even when only isolated cells are found in the sentinel node, the rate of nonsentinel node metastasis is 4.1% (one of 24), and in cases of metastasis of less than 5 mm, 11.7% (four of 34). Thus, inguinofemoral lymphadenectomy is still recommended when metastasis of any size is found in the sentinel node. However, the clinical significance of isolated tumor cells and micrometastases in the sentinel lymph node remains unclear.

Moreover, other trials brought back the discussion on sentinel node safety and surgeon's experience. A study with inclusion criteria similar to those in GROINSS-V showed a high false-negative rate of 12.5% (seven of 56 cases). The authors stated that the main factor responsible for the high false-negative rate was the surgeons' experience [49].

Recently, Levenback *et al.* [50▪▪] published data from Gynecologic Oncology Group trial 173 (GOG 173), a prospective, multi-institution validation trial that included 452 patients with tumors up to 6 cm who received sentinel node procedure followed by inguinofemoral lymphadenectomy. There was no requirement on surgeon skill verification. After almost 10 years of accrual, the overall prevalence of lymph node metastases was 31.6%, the sentinel node was the only positive node in 55.3% of node-positive patients, and 23% of positive sentinel nodes were detected by ultrastaging immunostaining. Overall false-negative predictive value was 3.7%. However, in women with tumor less than 4 cm, it was only 2.0%, which is quite similar to the GROINSS-V study [45]. Of note, of the 11 false-negative patients, six occurred in up to the third case from an institution.

Together, the results of the GOG 173 [50▪▪] and GROINSS-V [45] trials provide sufficient evidence that sentinel node biopsy should be offered to selected patients and better performed by well trained gynecologic oncologists.

After the introduction of sentinel node procedure, two unanswered questions have persisted. First, which patients would safely undergo only unilateral sentinel node procedure? Second, is it possible to have sentinel node biopsy after previous vulvar surgery?

For midline lesions, some authors had suggested that a complete inguinofemoral lymphadenectomy should be performed in the groin where sentinel node is not found [2,5]. Coleman *et al.* [51▪▪] recently addressed this issue and analyzed the data of 234 patients from the GOG 173 trial. They categorized the primary tumors into three groups based on the localization: lateral (>2 cm distant from midline), midline, or lateral ambiguous (located within 2 cm). Bilateral lymphoscintigraphy was found in 22% of lateral tumors, 58% of lateral ambiguous tumors, and 70% of midline tumors. No contralateral metastasis was found in patients with lateral ambiguous tumors and unilateral lymphoscintigraphy, but was found in four of 32 (12.5%) patients with midline tumors. Interestingly, there was an unexpected 22% contralateral lymphoscintigraphy for the lateral tumors, whereas 30% unilateral lymphoscintigraphy for the midline tumors. The authors suggested that patients with lateral ambiguous tumor and unilateral drainage on lymphoscintigraphy might safely undergo unilateral sentinel node biopsy. If this hypothesis is validated, it will be possible to omit unnecessary contralateral groin dissection.

The feasibility and safety of sentinel node biopsy after vulvar surgery were examined by three recent studies. Woelber *et al.* [52▪] studied 74 patients who received sentinel node biopsy concomitant to vulvar surgery, whereas 32 patients had vulvar surgery before the secondary sentinel node procedure. Sentinel node detection was possible in all patients. There were no groin recurrences in the secondary sentinel node and 5.4% in the primary sentinel node. This high recurrence rate may be explained by the inclusion of tumors greater than 4 cm. Ennik *et al.* [53] corroborate this finding in 27 cases, in which previous excision of a primary vulvar malignancy did not impair sentinel node detection. Finally, in the GOG 173 study [50▪▪], sentinel node detection rate (87.5%; 42 of 48 cases) was similar in patients who had a prior wide local excision compared to patients without previous surgery (93.1%; 376 of 404 cases) ($P = 0.15$). In summary, sentinel node procedure after previous vulvar surgery is feasible and may reflect the groin status.

It is important to note that in the case of previous sentinel node biopsy and a recurrent vulvar tumor, the patient should have at that time an inguinofemoral lymphadenectomy [44].

We conclude that patients with unifocal vulvar cancer, tumor size less than 4 cm, and clinically negative groins should undergo sentinel node procedure with combined technique. The procedure should be performed in centers with an experienced multidisciplinary team. The sentinel node should be analyzed by 'ultrastaging' and if it is positive, a systematic inguinofemoral lymphadenectomy is recommended.

Copyright © Lippincott Williams & Wilkins. Unauthorized reproduction of this article is prohibited.

Nevertheless, radiotherapy as a definitive approach instead of lymphadenectomy for groin treatment after a positive sentinel node is being addressed by the ongoing trial GROINSS-V-II. The main objective is to evaluate whether inguinofemoral lymphadenectomy could be omitted in patients with a positive sentinel node if they receive adjuvant radiotherapy.

ADVANCED VULVAR CANCER

It is challenging to choose the best treatment for patients with locally advanced disease. In the case of resectable disease, exenterative procedures have been described [54]. However, these procedures are associated with high morbidity rates, significant physical and psychological impact, and permanent colostomy and urostomy [54].

Therefore, primary radiotherapy with concomitant chemotherapy in neoadjuvant setting has become an important choice with the intention to achieve resectability with organ-sparing and less radical procedures.

However, a high-related toxicity is expected, although with high response rates and resectability rates of 63–92%, respectively [55]. None of the studies showed a benefit for either treatment option, and no differences in morbidity could be demonstrated [56].

In summary, data on neoadjuvant chemoradiation for advanced vulvar cancer are still limited. However, we recommend neoadjuvant chemoradiation for advanced vulvar cancer patients, in whom tumors could only be primarily resected by exenterative procedures.

CONCLUSION

Surgery is the cornerstone for staging and treatment of vulvar cancer. Early-stage disease has a very good prognosis and treatment should be individualized.

Primary tumor may be safely treated with radical/wide local resection with intended surgical margins of 2 cm and final pathological margin of at least 1 cm. In the case of suspicious lesion or multifocal disease, radical vulvectomy should be performed.

For patients who have unifocal disease, tumor size less than 4 cm, and clinically and imaging negative groins, sentinel node procedure with combined technique should be offered (blue dye and lymphoscintigraphy). In the case of clinically positive node or positive sentinel node, a systematic inguinofemoral lymphadenectomy should be performed.

Neoadjuvant chemoradiation is indicated for advanced tumors that could only be primarily resected by exenterative procedures or for fixed enlarged inguinofemoral lymph nodes.

Acknowledgements

None.

Conflicts of interest

The authors state that there is no conflict of interest.

REFERENCES AND RECOMMENDED READING

Papers of particular interest, published within the annual period of review, have been highlighted as:
- ■ of special interest
- ■■ of outstanding interest

1. Hacker NF. Vulvar cancer. In: Berek JS, Hacker NF, editors. Berek & Hacker's gynecologic oncology, 5th ed. Philadelphia: Williams & Wilkins; 2010. pp. 576–592.
2. De Hullu JA, van der Zee AG. Surgery and radiotherapy in vulvar cancer. Crit Rev Oncol Hematol 2006; 60:38–58.
3. Homesley HD, Bundy BN, Sedlis A, *et al.* Assessment of current International Federation of Gynecology and Obstetrics staging of vulvar carcinoma relative to prognostic factors for survival (A Gynecologic Oncology Group Study). Am J Obstet 1991; 164:997–1004.
4. Baiocchi G, Silva Cestari FM, Rocha RM, *et al.* Prognostic value of the number and laterality of metastatic inguinal lymph nodes in vulvar cancer: revisiting the FIGO staging system. Eur J Surg Oncol 2013; 39:780–785.
5. Woelber L, Kock L, Gieseking F, *et al.* Clinical management of primary vulvar cancer. Eur J Cancer 2011; 47:2315–2321.
6. Kelley 3rd JL, Burke TW, Tornos C, *et al.* Minimally invasive vulvar carcinoma: an indication for conservative surgical therapy. Gynecol Oncol 1992; 44:240–244.
7. Magrina JF, Webb MJ, Gaffey TA, *et al.* Stage I squamous cell cancer of the vulva. Am J Obstet Gynecol 1979; 134:453–459.
8. Sidor J, Diallo-Danebrock R, Eltze E, *et al.* Challenging the concept of microinvasive carcinoma of the vulva: report of a case with regional lymph node recurrence and review of the literature. BMC Cancer 2006; 6:157.
9. Stehman FB, Bundy BN, Thomas G, *et al.* Groin dissection versus groin radiation in carcinoma of the vulva: a Gynecologic Oncology Group study. Int J Radiat Oncol Biol Phys 1992; 24:389–396.
10. Van der Velden J, Fons G, Lawrie TA. Primary groin irradiation versus primary groin surgery for early vulvar cancer. Cochrane Database Syst Rev 2011; CD002224.
11. Taussig FJ. Cancer of the vulva: an analysis of 155 cases. Am J Obstet Gynecol 1940; 40:764–779.
12. Way S. Carcinoma of the vulva. Am J Obstet Gynecol 1960; 79:692–697.
13. Andersen BL, Hacker NF. Psychosexual adjustment after vulvar surgery. Obstet Gynecol 1983; 62:457–462.
14. Magrina JF, Gonzalez-Bosquet J, Weaver AL, *et al.* Primary squamous cell cancer of the vulva: radical versus modified radical vulvar surgery. Gynecol Oncol 1998; 71:116–121.
15. Lin JY, Du Beshter B, Angel C, *et al.* Morbidity and recurrence with modifications of radical vulvectomy and groin dissection. Gynecol Oncol 1992; 47:80–86.
16. Hacker NF, Leuchter RS, Berek JS, *et al.* Radical vulvectomy and bilateral inguinal lymphadenectomy through separate groin incisions. Obstet Gynecol 1981; 58:574–579.
17. De Hullu JA, Hollema H, Lolkema S, *et al.* Vulvar carcinoma. The price of less radical surgery. Cancer 2002; 95:2331–2338.
18. Burger MP, Hollema H, Emanuels AG, *et al.* The importance of the groin node status for the survival of T1 and T2 vulval carcinoma patients. Gynecol Oncol 1995; 57:327–334.
19. Schulz MJ, Penalver M. Recurrent vulvar carcinoma in the intervening tissue bridge in early invasive stage I disease treated by radical vulvectomy and bilateral groin dissection through separate incisions. Gynecol Oncol 1989; 35:383–386.
20. Grimshaw RN, Murdoch JB, Monaghan JM. Radical vulvectomy and bilateral inguinal–femoral lymphadenectomy through separate incisions – experience with 100 cases. Int J Gynecol Cancer 1993; 3:18–23.
21. Christopherson W, Buchsbaum HJ, Voet R, *et al.* Radical vulvectomy and bilateral groin lymphadenectomy utilizing separate groin incisions: report of a case with recurrence in the intervening skin bridge. Gynecol Oncol 1985; 21:247–251.
22. Rose PG. Skin bridge recurrences in vulvar cancer: frequency and management. Int J Gynecol Cancer 1999; 9:508–511.
23. Hopkins MP, Reid GC, Morley GW, Radical vulvectomy. The decision for the incision. Cancer 1993; 72:799–803.
24. Siller BS, Alvarez RD, Conner WD, *et al.* T2/3 vulva cancer: a case–control study of triple incision versus en bloc radical vulvectomy and inguinal lymphadenectomy. Gynecol Oncol 1995; 57:335–339.

Copyright © Lippincott Williams & Wilkins. Unauthorized reproduction of this article is prohibited.

25. Ansink A, van der Velden J. Surgical interventions for early squamous cell carcinoma of the vulva. Cochrane Database Syst Rev 2000; CD002036.
26. DiSaia PJ, Creasman WT, Rich WM. An alternate approach to early cancer of the vulva. Am J Obstet Gynecol 1979; 133:825–832.
27. Burke TW, Levenback C, Coleman RL, *et al.* Surgical therapy of T1 and T2 vulvar carcinoma: further experience with radical wide excision and selective inguinal lymphadenectomy. Gynecol Oncol 1995; 57:215–220.
28. Heaps JM, Fu YS, Montz FJ, *et al.* Surgical–pathologic variables predictive of local recurrence in squamous cell carcinoma of the vulva. Gynecol Oncol 1990; 38:309–314.
29. Chan JK, Sugiyama V, Pham H, *et al.* Margin distance and other clinicopathologic prognostic factors in vulvar carcinoma: a multivariate analysis. Gynecol Oncol 2007; 104:636–641.
30. Palaia I, Bellati F, Calcagno M, *et al.* Invasive vulvar carcinoma and the question of the surgical margin. Int J Gynaecol Obstet 2011; 114:120–123.
31. ■ Ioffe YJ, Erickson BK, Foster KE, *et al.* Low yield of residual vulvar carcinoma and dysplasia upon re-excision for close or positive margins. Gynecol Oncol 2013; 129:528–532.
This study evaluates the prevalence of residual carcinoma after re-excision indicated for close or positive margins.
32. Groenen SM, Timmers PJ, Burger CW. Recurrence rate in vulvar carcinoma in relation to pathological margin distance. Int J Gynecol Cancer 2010; 20:869–873.
33. Woelber L, Choschzick M, Eulenburg C, *et al.* Prognostic value of pathological resection margin distance in squamous cell cancer of the vulva. Ann Surg Oncol 2011; 18:3811–3818.
34. Maggino T, Landoni F, Sartori E, *et al.* Patterns of recurrence in patients with squamous cell carcinoma of the vulva. A multicenter CTF study. Cancer 2000; 89:1161–1222.
35. Stehman FB, Bundy BN, Ball H, *et al.* Sites of failure and times to failure in carcinoma of the vulva treated conservatively: a Gynecologic Oncology Group study. Am J Obstet Gynecol 1996; 174:1128–1132.
36. Preti M, Ronco G, Ghiringhello B, *et al.* Recurrent squamous cell carcinoma of the vulva: clinicopathologic determinants identifying low risk patients. Cancer 2000; 88:1869–1876.
37. ■■ Viswanathan AN, Pinto AP, Schultz D, *et al.* Relationship of margin status and radiation dose to recurrence in postoperative vulvar carcinoma. Gynecol Oncol 2013; 130:545–549.
In this recent large trial, the authors corroborate the current recommendations and conclude that recurrences occur with margins up to 9 mm. Moreover, they correlated recurrence and adjuvant radiotherapy dose, whereas those who received at least 56 Gy had a lower risk of local relapse.
38. Stehman FB, Bundy BN, Dvoretsky PM, *et al.* Early stage I carcinoma of the vulva treated with ipsilateral superficial lymphadenectomy and modified radical hemivulvectomy: a prospective study of the Gynecologic Oncology Group. Obstet Gynecol 1992; 79:490–497.
39. Gordinier ME, Malpica A, Burke TW, *et al.* Groin recurrence in patients treated with negative nodes on superficial inguinal lymphadenectomy. Gynecol Oncol 2003; 90:625–628.
40. Berman ML, Soper JT, Creasman WT, *et al.* Conservative surgical management of superficially invasive stage I vulvar carcinoma. Gynecol Oncol 1989; 35:352–357.
41. Kirby TO, Rocconi RP, Numnum TM, *et al.* Outcomes of stage I/II vulvar cancer patients after negative superficial inguinal lymphadenectomy. Gynecol Oncol 2005; 98:309–312.
42. Selman TJ, Luesley DM, Acheson N, *et al.* A systematic review of the accuracy of diagnostic tests for inguinal lymph node status in vulvar cancer. Gynecol Oncol 2005; 99:206–214.
43. De Hullu JA, Oonk MH, Ansink AC, *et al.* Pitfalls in the sentinel lymph node procedure in vulvar cancer. Gynecol Oncol 2004; 94:10–15.
44. Oonk MH, de Hullu JA, van der Zee AG. Current controversies in the management of patients with early-stage vulvar cancer. Curr Opin Oncol 2010; 22:481–486.
45. Van der Zee AG, Oonk MH, Hullu JA, *et al.* Sentinel node dissection is safe in the treatment of early-stage vulvar cancer. J Clin Oncol 2008; 26:884–889.
46. Rodolakis A, Diakomanolis E, Voulgaris Z, *et al.* Squamous vulvar cancer: a clinically based individualization of treatment. Gynecol Oncol 2000; 78 (3 Pt 1):346–351.
47. Bell JG, Lea JS, Reid GC. Complete groin lymphadenectomy with preservation of the fascia lata in the treatment of vulvar carcinoma. Gynecol Oncol 2000; 77:314–318.
48. Oonk MH, van Hemel BM, Hollema H, *et al.* Size of sentinel-node metastasis and chances of nonsentinel-node involvement and survival in early stage vulvar cancer: results from GROINSS-V, a multicentre observational study. Lancet Oncol 2010; 11:646–652.
49. Radziszewski J, Kowalewska M, Jedrzejczak T, *et al.* The accuracy of the sentinel lymph node concept in early stage squamous cell vulvar carcinoma. Gynecol Oncol 2010; 116:473–477.
50. ■■ Levenback CF, Ali S, Coleman RL, *et al.* Lymphatic mapping and sentinel lymph node biopsy in women with squamous cell carcinoma of the vulva: a gynecologic oncology group study. J Clin Oncol 2012; 30:3786–3791.
A large, prospective, multi-institution validation trial of sentinel node biopsy. All patients had sentinel node biopsy followed by groin dissection. Together, the results of this trial and GROINSS-V trial provide sufficient evidence that sentinel node biopsy should be offered to selected patients and by well trained gynecologic oncologists. They also suggest that sentinel node biopsy may be performed in patients with previous surgery of primary tumor.
51. ■■ Coleman RL, Ali S, Levenback CF, *et al.* Is bilateral lymphadenectomy for midline squamous carcinoma of the vulva always necessary? An analysis from Gynecologic Oncology Group (GOG) 173. Gynecol Oncol 2013; 128:155–159.
This study determined the relationship between tumor distance from midline and bilaterality of sentinel node biopsy. The authors suggest that both lateral (>2 cm distant from midline) and lateral ambiguous tumors (located within 2 cm) that have unilateral drainage on lymphoscintigraphy may safely undergo only unilateral sentinel node biopsy.
52. ■ Woelber L, Grimm D, Vettorazzi E, *et al.* Secondary sentinel node biopsy after previous excision of the primary tumor in squamous cell carcinoma of the vulva. Ann Surg Oncol 2013; 20:1701–1706.
This study did not find difference in sentinel biopsy detection rate for patients with previous primary tumor resection compared to no previous surgery. It suggests that sentinel node biopsy may be safely performed in patients with primary tumor previous surgery.
53. Ennik TA, Allen DG, Bekkers RL, *et al.* Effects of previous surgery on the detection of sentinel nodes in women with vulvar cancer. Int J Gynecol Cancer 2011; 21:1679–1683.
54. Hoffman MS. Squamous-cell carcinoma of the vulva: locally advanced disease. Best Pract Res Clin Obstet Gynaecol 2003; 17:635–647.
55. Van Doorn HC, Ansink A, Verhaar-Langereis M, *et al.* Neoadjuvant chemoradiation for advanced primary vulvar cancer. Cochrane Database Syst Rev 2006; CD003752.
56. Shylasree TS, Bryant A, Howells RE. Chemoradiation for advanced primary vulval cancer. Cochrane Database Syst Rev 2011; 4:CD003752.

Copyright © Lippincott Williams & Wilkins. Unauthorized reproduction of this article is prohibited.